

More than just a bruise: Recognizing child physical abuse

ABSTRACT: Bruising in children is a common and often benign form of trauma that does not require investigation or intervention. However, bruising in infants is rare, and in children who have been physically abused it is the most common injury seen. Identifying inflicted trauma early in a case may prevent a more severe injury later. Distinguishing accidental from inflicted trauma requires recognizing injuries that suggest abuse: bruises on soft parts of the body such as the ears or neck, patterned or clustered bruises, bruises that are not consistent with the mechanism of injury reported, and bruises that are not consistent with a child's developmental level. In cases where bruising is found, the clinician should obtain a complete medical history and document all findings from a thorough physical examination. Physicians are required by law to report situations that may indicate child abuse. Current medical literature and recently published evidence-based guidelines can best inform the challenging decision-making process that might lead to reporting.

This article has been peer reviewed.

Bruising in children poses a diagnostic challenge to health care providers. Bruising can be caused by an underlying medical condition, accidental injury, or physical abuse. It is estimated that over 50% of children older than 1 year will have bruising from minor accidental injury.¹⁻⁴ However, bruising is also the most common injury in children who have been physically abused. Distinguishing accidental bruising from inflicted injury can be difficult for clinicians. Recent literature offers guidelines to assist medical professionals in distinguishing between abusive bruising and accidental bruising.⁵ The literature also suggests that bruising may be the first sign of physical abuse and that there is a link between early abusive injury and later severe injury.⁶⁻⁸ In almost 40% of fatal or near-fatal cases, physically abused children will have a history of a minor injury such as bruising, and recent research suggests health care providers are often aware of the minor injury.⁶ Medical practitioners have a unique opportunity to identify abuse before it escalates, but in order to intervene effectively they must possess a good understanding of when a bruise may be “more than just a bruise.” They must be able to:

- Distinguish between accidental injury and inflicted trauma.

- Manage infants and children who present with suspicious bruising.
- Appreciate the severity and significance of any bruising in an infant.

Case report

In a case illustrating the importance of intervention, a 2-month-old baby boy presented to a family doctor with swelling to the right side of his head. There was no reported history of trauma and the infant appeared well otherwise. The mother remarked that the baby “seemed to bruise easily” and that she had noticed bruises on his forehead and cheek, as well as on his fingertips a few weeks previously. The bruises had since resolved.

The child was born at term following an uneventful pregnancy and received vitamin K. When examined in the family doctor's office, the child looked well and was alert and active. The only finding of note was a right-sided cephalohematoma (**Figure 1**). No investigations were conducted and the doctor reassured the mother that the child appeared well.

Two weeks later, the infant presented to the local hospital emergency

Dr Chapple is the director of pediatrics at Royal Inland Hospital in Kamloops and a clinical instructor in the University of British Columbia Southern Medical Program at UBC's Okanagan campus.

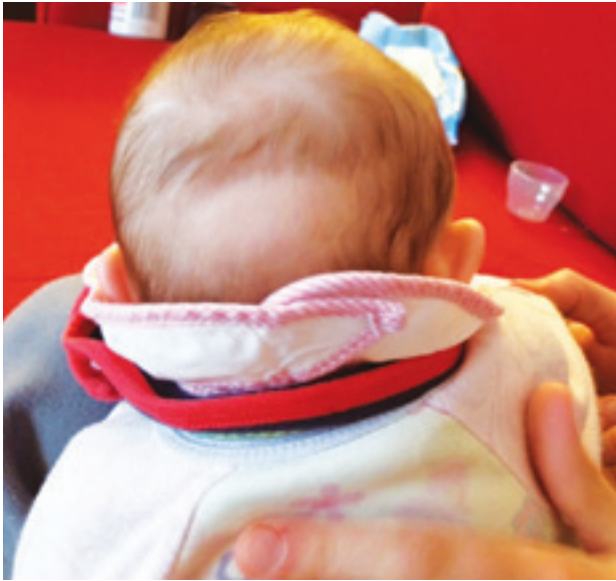

Figure 1. Right-sided cephalohematoma seen by family doctor during an office visit.

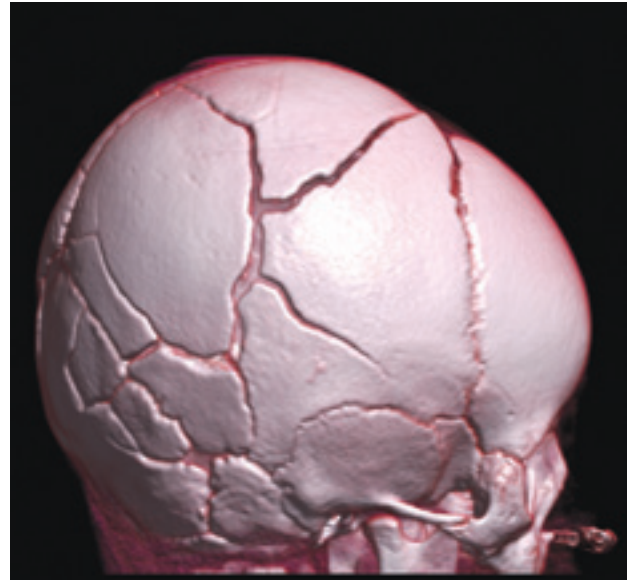


Figure 2. Right parietal skull fracture revealed by CT scan when unresponsive infant was brought to emergency department 2 weeks after office visit.

department. He was unresponsive and seizing. The parents stated that over the previous few days the baby had seemed sleepier and was feeding less. The father also noted that a similar scalp swelling had appeared on the left side of the baby's head the day before presentation, although once again no history of trauma was provided by the parents.

A CT scan of the head revealed acute subdural hemorrhage, cerebral edema, and biparietal skull fractures (Figure 2). A skeletal survey revealed further healing fractures of the ribs. Given the signs of abuse, child protection officials were contacted and an investigation was initiated.

Distinguishing accidental from inflicted bruising

Bruises on an infant or child may be the reason for the medical visit or may be an incidental finding. When evaluating bruises, clinicians need to consider the following characteristics.

Development—mobile vs nonmobile

“Those who don't cruise, rarely bruise.”² The risk of bruising is directly related to a child's level of independent mobility.¹⁻⁴ Sugar and colleagues examined close to 1000 healthy children younger than 3 and found that bruising was rare in children younger than 6 months (0.6%) and uncommon in children younger than 9 months (1.7%).² Further, almost 20% of infants, regardless of age, who begin to crawl and cruise (walk with support) develop bruising, and over 50% of independently walking children have bruises. There have been numerous case reports of infants who ultimately suffered a fatal injury after being found to have minor bruising, in some cases a single bruise, that was not investigated.⁶⁻⁹ Sheets and colleagues conducted a case-control retrospective study to determine how often abused infants have a previous history of injury.⁶ They defined such a “sentinel” injury as “a previous injury

reported in the medical history that was suspicious for abuse because the infant could not cruise or the explanation was implausible.” Bruising was the most common sentinel injury and was found in almost 25% of infants with abusive head trauma. In this study, health care providers were aware of the sentinel injury in 42% of the abuse cases. As illustrated by our case report, the bruising on the infant was historical and appeared insignificant, yet it was eventually revealed to be a sentinel injury. Any bruising in a nonmobile infant, no matter how minor, should prompt further investigation.

Location—hard vs soft

Mobile children are often found to have bruising due to trauma from childhood activity. Accidental bruising is most often found over hard bony prominences, usually on the front of the child's body.^{1-4,10} Accidental bruising in a mobile child most commonly occurs on the shins, knees, elbows,

forehead, nose, chin, and the occipital scalp. In abused children, bruising can occur anywhere on the body, although it is most commonly found on the head.¹ In addition, inflicted bruising is often found on soft parts of the body, namely the cheeks, ears, neck, trunk, buttocks, and arms.¹¹ Pierce and colleagues devised a clinical decision tool to predict the likelihood of physical abuse in children

accident in a public setting that accounts for the bruising in the TEN region on a child or in any region on the infant?

This model was found to have a sensitivity of 97% and a specificity of 84% for predicting abuse. As illustrated by our case report, an investigation of the first instance of bruising, which was likely inflicted, might have prevented further abusive injuries.

Bruising predictive of abuse was found on the torso, ear, or neck (TEN) region in children up to 4 years of age, or in any location in infants under 4 months of age.

younger than 4 years admitted to the pediatric intensive care unit because of trauma.⁵ Bruising characteristics of inflicted and accidental trauma were compared, specifically the number of bruises and their location. Bruising predictive of abuse was found on the torso, ear, or neck (TEN) region in children up to 4 years of age, or in any location in infants under 4 months of age. From their data, Pierce and colleagues developed the TEN-4 body region and age-based bruising clinical decision tool, which poses three screening questions:

- Is there bruising in the TEN region of the body of a child up to 4 years of age?
- Is there bruising anywhere on the body of an infant under 4 months of age?
- Is there a confirmed witnessed ac-

Number of bruises

Over 50% of mobile children will have bruising, but what number of bruises is considered normal? In the previously mentioned study by Sugar and colleagues, cruising children exhibited one to five bruises and walking children had one to eleven bruises (mean 2.4 bruises per injured child).² The majority of these bruises (93%) were found over bony prominences. Labbe and Caouette studied almost 1500 children from age 0 months to 17 years and found that 17% of children had 5 skin injuries and 4% had 10 or more skin injuries.³ Less than 1% of the total sample of children had 15 or more skin injuries. The majority of the skin injuries were bruises, but children also exhibited abrasions and scratches. Labbe and Caouette concluded that it was rare to find 15 or

more skin injuries in any child, and it was especially rare to find *any* bruises in an infant under 9 months of age.

Patterned or clustered bruises

It is well accepted that bruising on the skin that depicts an object or pattern is highly suspicious for inflicted trauma.¹¹⁻¹³ For example, a linear bruise may indicate that the child was hit with a stick-like object, and parallel linear bruises may indicate that the child was slapped with a hand. Clusters of bruises are often found in abused children and are thought to indicate defensive injuries, or grab marks, especially if they are found on the upper arms and outer thighs.^{11,12} Finally, the presence of petechiae in association with bruising has been found to be a strong indicator of abuse.^{11,14} Nayak and colleagues reported finding petechiae more frequently in cases of abuse (22%) than in cases where abuse had been ruled out (2%).¹⁴ In this study, petechiae were 6 times more likely to be seen in children with inflicted injuries. The absence of petechiae, however, was not a significant factor for excluding abuse.

Mechanism of injury

If the mechanism of injury reported during history taking is not consistent with the bruising seen on examination or with the child's developmental level, physical abuse should be considered. As well, if the injury was not witnessed or if there is no explanation offered, further evaluation may be necessary, depending on the physical findings (e.g., bruising in the TEN region). Active, mobile children commonly fall and, not surprisingly, falls often result in accidental bruising. Chang and Tsai studied the pattern of craniofacial injuries associated with slips, trips, and falls in 750 children younger than 12 years.¹⁵

Most of the injuries were to the prominent areas of the anterior head (forehead, nose, upper lip, and chin) and to the occipital area, and 98% of the patients suffered no or only mild brain injuries.

Medical evaluation

In 2013, the Child and Youth Maltreatment Section of the Canadian Pediatric Society published a practice point about the medical assessment of bruising in suspected child maltreatment cases.¹⁶ The authors provided a thorough evidence-based approach for evaluating bruising in child maltreatment cases. This approach includes history taking, physical examination, and further investigation and consultation.

History

In addition to direct questioning about the timing and the mechanism of the bruising noted on a child, the clinician should obtain a complete medical history to rule out an underlying bleeding disorder. A history of bleeding, bruising, or other injuries should be documented, along with any history of prolonged bleeding with epistaxis, minor injuries, or procedures (e.g., circumcision, dental extractions), and any recent viral illness or history of systemic symptoms such as fever, pallor, and fatigue that might indicate an underlying medical condition (e.g., idiopathic thrombocytopenic purpura, leukemia). Family members with bleeding problems such as menorrhagia, epistaxis, or prolonged bleeding after surgery or childbirth should be identified. Finally, a complete psychosocial history should be documented to identify risk factors for child maltreatment, including young parental age, parental substance use, domestic violence, and financial stressors.¹⁷

Physical examination

The finding of significant bruising in a child, or any bruising in an infant, warrants a thorough physical examination. The clinician should clearly document the location, size, color, and shape of any bruise, in addition to the child's general appearance and growth parameters (including head circumference). The entire body of the child or infant should be thoroughly examined for other areas of bruising that may not be immediately obvious, especially on the trunk, neck, buttocks, genitalia (including the frenulum), hands, feet, and behind or on the ears. The mouth and nares require careful examination for any trauma, especially in infants, as intraoral injuries and nasal bleeding are highly suspicious for physical abuse. Any evidence of abdominal trauma, tenderness, distension, abnormal masses, or hepatosplenomegaly should be documented. The clinician should perform a complete musculoskeletal examination, noting any tenderness, swelling, deformity, or limitations to range of motion. The neurological status of the child should be documented as well, especially if there is bruising to the head or face.

Investigation and consultation

Any bruising in a nonmobile infant is a medical emergency that warrants immediate investigation. Initial laboratory screening should include a complete blood count, prothrombin time (PT), international normalized ratio (INR), activated partial thromboplastin time (APTT), fibrinogen, factor VIII and IX levels, and assays for von Willebrand disease. This initial screening panel evaluates for hematological conditions that are more common than 1 per 500 000.¹⁸ Additional imaging investigations may be indicated to assess for the possibility of occult head or skeletal trauma.

All bruising in babies and bruising in mobile children that does not appear to be accidental require urgent consultation with a pediatrician or a clinician who specializes in child maltreatment. In British Columbia, Suspected Child Abuse and Neglect (SCAN) teams are located in Prince George, Kamloops, Surrey, Vancouver, and Nanaimo. Each team consists of physicians, nurses, social workers, and psychologists with expertise in child maltreatment. The SCAN teams operate collaboratively with local law enforcement and child protection social workers. The child abuse physicians can support health care providers who are concerned about a child and can offer advice regarding specific laboratory testing and medical imaging.

Reporting to child protection services

Physicians are required by law to report situations that may indicate child abuse. In BC, reports are made to the Ministry of Children and Family Development or to a designated Aboriginal authority. Despite this legal requirement, physical abuse continues to be underreported by health care providers. Bruises have been identified as the most common suspicious injury not reported.¹⁹ In some cases, failure to report may be due to not recognizing abusive injuries; however, Sege and colleagues found that although primary health care providers and child abuse experts agreed on the concern for abuse in 81% of cases, primary health care providers would not have reported 21% of injuries that experts would have reported.²⁰ Underreporting may also occur if physicians feel that reporting their concerns could jeopardize patient rapport and the relationship with families that has been nurtured over time. The process may be

facilitated by explaining to caregivers that bruising represents an injury that warrants medical investigation and keeping the focus on the health of the child rather than on the caregivers as potential offenders.

All bruising in babies and bruising in mobile children that does not appear to be accidental require urgent consultation with a pediatrician or a clinician who specializes in child maltreatment.

Summary

One of the most challenging clinical scenarios begins with a finding of unexplained bruising in a pediatric patient during a routine examination. The clinician must determine if the bruising is likely to be accidental, due to an underlying medical condition, or the result of physical abuse. Bruising that suggests physical abuse requires further medical investigation and mandatory reporting to child protection services. Consultation with pediatric or child maltreatment specialists is recommended. By recognizing suspicious bruising, practitioners may be able to prevent subsequent injuries that could result in significant morbidity and mortality.

Competing interests

None declared.

References

1. Maguire S, Mann MK, Sibert J, et al. Are there patterns of bruising in childhood which are diagnostic or suggestive of abuse? A systematic review. Arch Dis Child 2005;90:182-185.

2. Sugar NF, Taylor JA, Feldman KW, et al. Bruises in infants and toddlers: Those who don't bruise rarely bruise. Arch Pediatr Adolesc Med 1999;153:399-403.

3. Labbe J, Caouette G. Recent skin injuries in normal children. Pediatrics 2001; 108:271-276.

4. Maguire S. Which injuries may indicate child abuse? Arch Dis Child Educ Pract Ed 2010;95:170-177.

5. Pierce MC, Kaczor K, Aldridge S, et al. Bruising characteristics discriminating physical child abuse from accidental trauma. Pediatrics 2010;125:67-74.

6. Sheets LK, Leach ME, Koszewski IJ, et al. Sentinel injuries in infants evaluated for child physical abuse. Pediatrics 2013; 4:701-707.

7. Petska HW, Sheets LK, Knox BL. Facial bruising as a precursor to abusive head trauma. Clin Pediatr (Phila) 2013;52:86-88.

8. Pierce MC, Smith S, Kaczor K. Bruising in infants: Those with a bruise may be abused. Pediatr Emerg Care 2009;25: 845-847.

9. Feldman KW. The bruised premobile infant: Should you evaluate further? Pediatr Emerg Care 2009;25:37-39.

10. Maguire S, Mann M. Systematic reviews of bruising in relation to child abuse—What have we learnt: An overview of review updates. Evid Based Child Health 2013;8:255-263.

11. Kemp AM, Maguire SA, Nuttall D, et al. Bruising in children who are assessed for suspected physical abuse. Arch Dis Child 2014;99:108-113.

12. Swerdlin A, Berkowitz C, Craft N. Cutaneous signs of child abuse. J Am Acad Dermatol 2007;57:371-391.

13. Committee on Child Abuse and Neglect. American Academy of Pediatrics. When inflicted skin injuries constitute child abuse. Pediatrics 2002;110:644-645.

14. Nayak K, Spencer N, Shenoy M, et al. How useful is the presence of petechiae in distinguishing non-accidental from accidental injury? Child Abuse Negl 2006; 30:549-555.

15. Chang L, Tsai M. Craniofacial injuries from slip, trip, and fall accidents of children. J Trauma 2007;63:70-74.

16. Ward MG, Ornstein A, Niec A, et al. The medical assessment of bruising in suspected child maltreatment cases: A clinical perspective. Paediatr Child Health 2013;18:433-437.

17. Centers for Disease Control and Prevention. Child maltreatment: Risk and protective factors. January 2014. Accessed 25 June 2015. www.cdc.gov/violenceprevention/childmaltreatment/riskprotectivefactors.html.

18. Anderst JD, Carpenter SL, Abshire TC; Section on Hematology/Oncology and Committee on Child Abuse and Neglect of the American Academy of Pediatrics. Evaluation for bleeding disorders in suspected child abuse. Pediatrics 2013;131; e1314.

19. Flaherty EG, Sege RD, Griffith J, et al. From suspicion of physical abuse to reporting: Primary care clinician decision-making. Pediatrics 2008;122:611-619.

20. Sege R, Flaherty E, Jones R, et al. To report or not to report: Examination of the initial primary care management of suspicious childhood injuries. Acad Pediatr 2011;11:460-466. **BCMJ**