Robert McCormack, MD, FRCSC

The role of arthroscopy in the treatment of degenerative joint disease of the knee

Recent studies question the benefits of arthroscopic debridement for managing patients with osteoarthritis affecting a weight-bearing joint.

ABSTRACT: Degenerative joint disease is a common cause of knee symptoms and disability. The indication to proceed to surgery is usually the failure of standard nonsurgical treatments. Despite the success of joint replacement surgery, many clinicians choose to avoid this large, complex surgery if a minimally invasive ambulatory procedure can allow a patient to improve function and quality of life. This has led to the frequent use of arthroscopy to treat degenerative joints, especially knee joints. While a "scope" does qualify as minimally invasive, it is still important to consider the ratio of risks to benefits and the efficacy of arthroscopic debridement for degenerative joint disease of the knee.

The impact of osteoarthritis on the health care system is significant and continues to grow as our population ages. As there is no cure for degenerative joint disease (DJD), medical interventions have focused on symptom control. Unfortunately, none of the nonoperative measures are universally successful and some have significant risks. A minimally invasive day-care procedure that improves patient function and delays more extensive reconstruction is appealing. Arthroscopy is the most commonly performed orthopaedic procedure, one often associated with knee ligament reconstruction and treatment of meniscal tears. In addition, some estimates suggest that over 500 000 arthroscopies are performed in North America each year for the treatment of degenerative joint disease.[1] Recent studies have questioned the role of this procedure in the treatment of osteoarthritis, and there is a general consensus that it has been overused in the past. The goal of this article is to address the role of arthroscopic surgery in patients who have degenerative joint disease in the knee.

Proposed benefits

It has been proposed that arthroscopic lavage (wash out) of the knee joint can improve patient status by washing out inflammatory cytokines, cartilage fragments, and other debris from the joint. Formal joint debridement has also been reported to improve patient status by smoothing off unstable flaps of articular cartilage and possibly improving the weight distribution of the remaining articular cartilage.[2]

On the one hand, if there is an unstable meniscal fragment that is causing mechanical symptoms, such as locking, pain with sudden turns, or sharp intermittent pain, an arthroscopy can address that component of the patient's symptoms by trimming the unstable fragment. On the other hand, it is difficult to quantify the benefit of arthroscopic repair of the arthritic knee given the inability during arthroscopy to actually perform biological resurfacing in the face of diffuse degenerative changes and the extremely variable course of DJD.

Recent studies

Most of the orthopaedic studies regarding the role of arthroscopy in the treatment of DJD are of low quality and suffer from the same shortcomings seen in many other areas of medicine: variable selection criteria, inconsistent outcome measures, different surgical techniques, and publication

Dr McCormack is an associate professor in the Department of Orthopaedics at the University of British Columbia.

Figure 1. Anteroposterior weightbearing radiograph showing degenerative joint disease of the knee, particularly in the medial compartment.

bias. Through the 1980s and 1990s a variety of case reviews reported a reasonable rate of improvement with simple lavage or joint debridement in knees affected by osteoarthritis. The success rates ranged from 40% to 75%.[2] As might be expected, the benefits of simple lavage were, at best, transient and one small prospective randomized trial found that arthroscopic lavage was no more effective than closed needle lavage of the joint.[3]

The evidence supporting arthroscopic debridement was somewhat better, but improvement was frequently of short duration and studies showed that orthopaedic surgeons were actually poor at predicting which patients would improve.[4] In 2002 this technique came under close scrutiny when the results of a prospective randomized trial by Moseley and colleagues was published in the *New England Journal of Medicine*.[5] This trial captured a tremendous amount of attention because patients were randomized to one of three arms: arthroscopic lavage, arthroscopic debridement, or sham operation. The patients were assessed by a blinded independent assessor and the key finding was that there was no significant difference in pain or function between the sham operation and either of the arthroscopic surgery groups. As interesting as the results were, the design of the trial also captured a lot of attention. The placebo effect of surgery was neutralized by giving the patients in the sham operation an anaesthetic and creating the standard arthroscopic portals, without performing any surgery inside the knee.

The Moseley study created a furor among orthopaedic arthroscopists. Many criticized the design of the study and the fact that all subjects were males (in a female-dominated disease) and all came from a Veterans Affairs hospital (equivalent to workers' compensation patients). There were concerns that the patients had more severe disease than average and that the authors used a nonvalidated outcome measure. Nevertheless, several societies, including the American Rheumatological Association, came out with position statements that arthroscopy did not have a role in the treatment of osteoarthritis.

This controversy spawned further trials in a number of centres, and recently a prospective randomized clinical trial from the University of Western Ontario was published, again in the *New England Journal of Medicine*.[6] This Canadian trial by Kirkley and colleagues randomized patients to optimal medical treatment or optimal medical treatment plus arthroscopic debridement. The researchers defined the grade of arthritis more precisely and ensured that limb malalignment was not significant. The patients in both groups had similar age, BMI, and length of follow-up. Importantly, the researchers excluded patients with significant meniscal tears that were causing mechanical symptoms. The primary outcome was the validated, disease-specific WOMAC score.[7] The bottom line is that the trial addressed most of the criticisms of the Moseley trial. Interestingly, at 2 years follow-up, the WOMAC scores were not statistically different ($P = .22$) and with an absolute difference of less than 1% that did not meet the threshold of a clinically significant difference.

Significance of findings

What do these findings mean to the clinician? Degenerative joint disease of the knee (**Figure 1**) is common and family physicians often decide to order an MRI to assess the joint. Since the same degenerative process affecting the articular cartilage also affects the menisci, it is not surprising that most of these patients also have a degenerative tear of the meniscus (**Figure 2**). Unfortunately, the patient and physician frequently focus on the MRI results and forget clinical correlation. When there are significant degenerative changes most of the symptoms are related to the underlying degeneration. Asymptomatic meniscal tears are very common in this clinical situation and meniscal resection does not address the main pain generators. As the Moseley and Kirkley trials show, when there is significant degeneration, arthroscopic debridement including resection of degenerative meniscal tears (**Figure 3**) does not lead to improvement in patient outcomes, and may in fact lead to more rapid deterioration.

The one caveat to this is that the presence of significant mechanical symptoms (locking, significant catching, or instability secondary to a torn meniscus or loose body) is different from isolated joint line pain. These

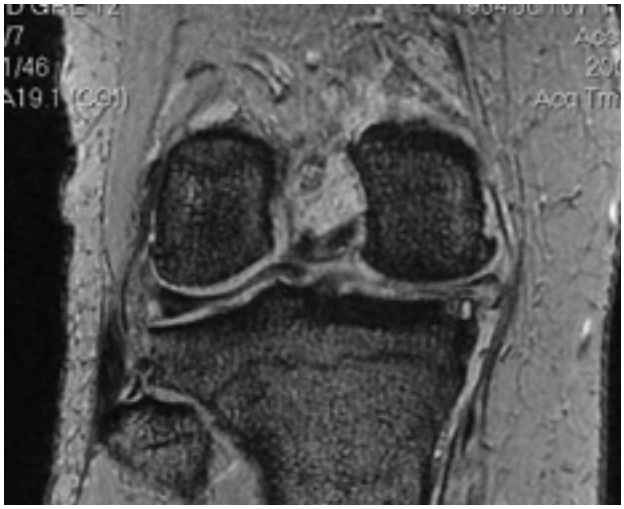

Figure 2. MRI showing degenerative tear of the medial meniscus. Degenerative joint disease can also be seen in the medial compartment.

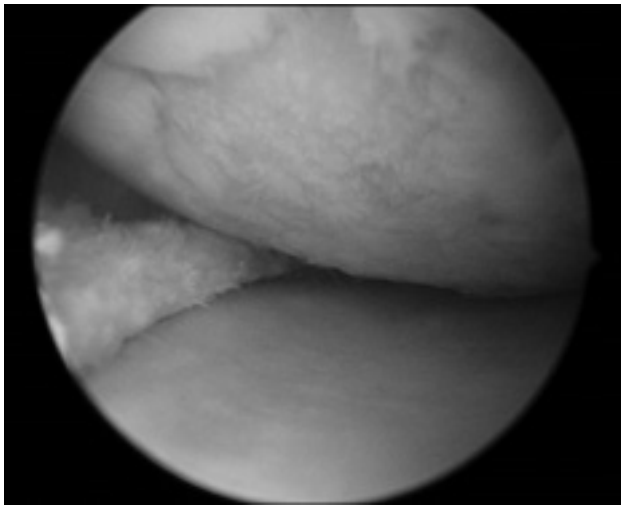

Figure 3. An intraoperative arthroscopic view showing loss of articular cartilage in the medial femoral condyle along with a degenerative medial meniscal tear.

mechanical problems are more predictably improved with arthroscopic resection of the torn meniscus or loose body. However, it is important to remember that there may well be residual symptoms, secondary to the underlying DJD. The role of the primary care physician is to educate patients that significant degenerative changes are not helped by an arthroscopic "clean out."

A second caveat is that occasionally there is an indication for a diagnostic arthroscopy in a degenerative joint, to better define the extent of damage or to determine the role of other procedures such as realignment osteotomies or unicompartmental arthroplasty. This may also apply to patients whose symptom severity is out of keeping with the radiographic evidence. The patient can have changes that appear mild on plain radiographs but when examined arthroscopically prove to be more severe with large focal defects in articular cartilage.

Even if arthroscopic debridement offers a small benefit, this needs to be balanced against the risks of the procedure. Complications, including deep venous thrombosis and pulmonary embolism, are not to be underestimated and have ranged in some series from 7% to 31%, with a higher prevalence in older patients.[8]

Conclusions

Recent high-quality trials suggest that in the absence of mechanical symptoms, arthroscopic debridement of the knee has a very limited role to play when managing significant degenerative joint disease.

Competing interests

None declared.

References

1. Owings MF, Kozak LJ. Ambulatory and inpatient procedures in the United States, 1996. National Center for Health Statistics. Vital health Stat 13 (139). 1998.
2. Calvert GT, Wright R. The use of arthroscopy in the athlete with knee osteoarthritis. Clin Sports Med 2005;24:133-152.
3. Chang, RW, Falconer J, Stulberg SD, et al. A randomized, controlled trial of arthroscopic surgery versus closed-needle joint lavage for patients with osteoarthritis of the knee. Arthritis Rheum 1993;36:289-296.
4. Dervin GF, Stiell IG, Rody K, et al. Effect of arthroscopic debridement for osteoarthritis of the knee on health-related quality of life. J Bone Joint Surg Am 2003;85A: 10-19.
5. Moseley JB, O'Malley K, Petersen N, et al. A controlled trial of arthroscopic surgery for osteoarthritis of the knee. New Engl J Med 2002;347:81-87.
6. Kirkley A, Birmingham TB, Litchfield RB, et al. A randomized trial of arthroscopic surgery for osteoarthritis of the knee. New Engl J Med 2008;359:1097-1107.
7. Bellamy N, Buchanan WW, Goldsmith CH, et al. Validation study of WOMAC: A health status instrument for measuring clinically important patient relevant outcomes to antirheumatic drug therapy in patients with osteoarthritis of the hip or knee. J Rheumatol 1988;15:1833-1840.
8. Sherman OH, Fox JM, Snyder SJ, et al. Arthroscopy—"no-problem surgery." An analysis of complications in two thousand six hundred and forty cases: J Bone Joint Surg Am 1986;68:256-265. BCMJ